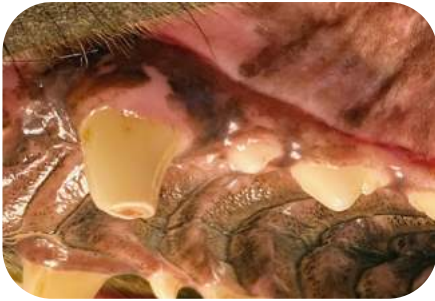

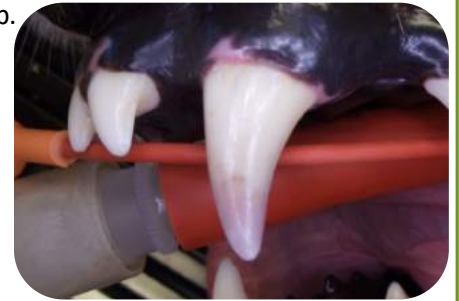Root Canal Therapy

When is root canal therapy (RCT) necessary?

When a tooth dies – often due to a tooth fracture, though occasionally due to a concussion of the pulp.

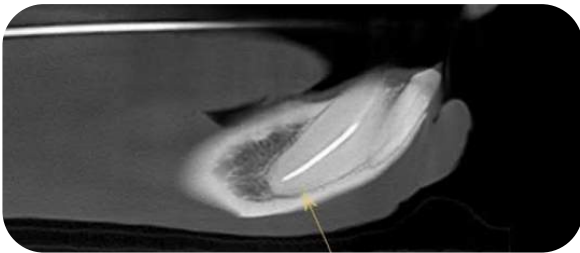


These are examples of fractured and non-vital teeth: the tooth on the left has pulp exposure and the tooth on the right has pulp death causing pink discoloration. Dogs and cats typically do not show it, but exposed pulp is painful and teeth with dead pulp will eventually abscess.



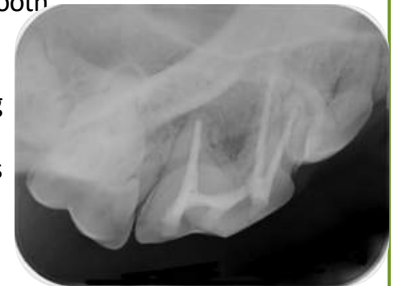What is the success rate of RCT?

- In dogs, almost 95% of root canals are successful in preventing or resolving inflammation or abscess formation in the bone around the tooth.
- To be able to tell whether treatment was successful, recheck dental x-rays and/or cone-beam CT are necessary, and recommended 6 months after surgery and then annually at the time the teeth are cleaned.



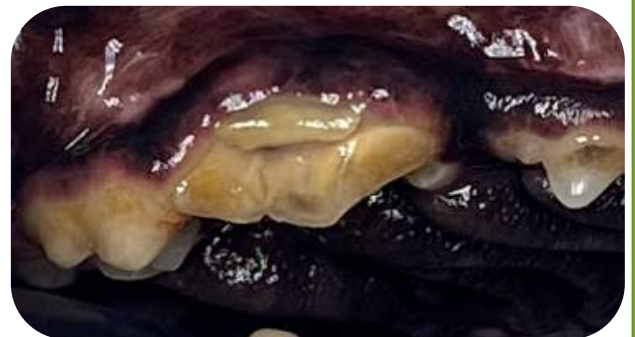Are there other options for broken teeth or teeth with dead pulp?

- The only other good option is extraction (removing the tooth completely).
- “Keeping an eye on it” is NOT a good option. It’s just a matter of time before an abscess forms and bone is destroyed around the tooth
- It may take months or even years until there is visible pus or swelling of the face, but the inflammatory process is extremely painful even without these signs.
- Animals hide this pain!

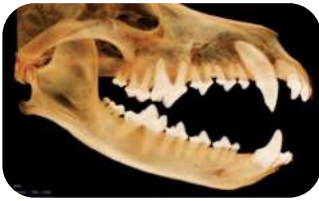

When is root canal therapy not possible?

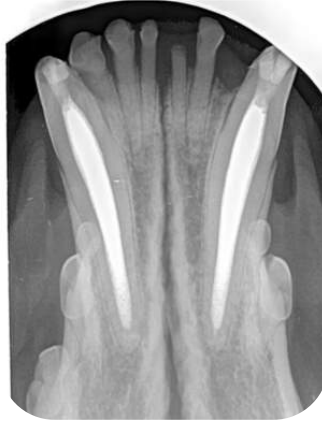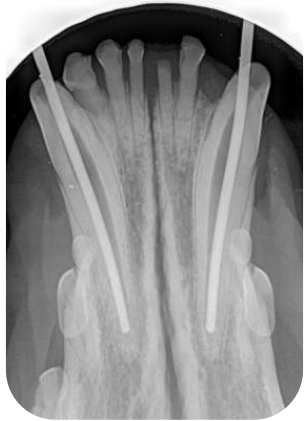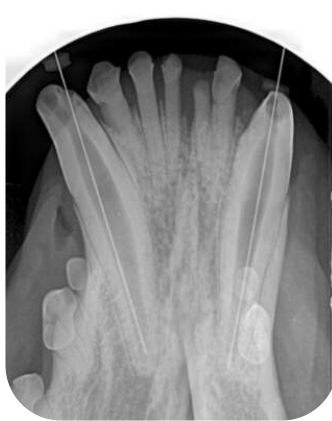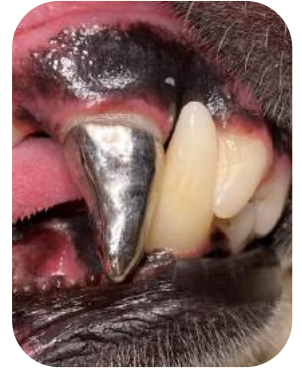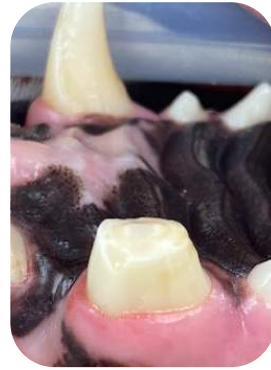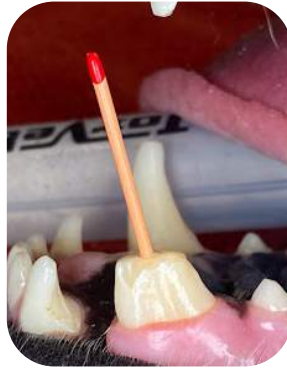
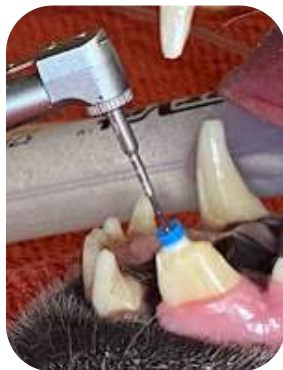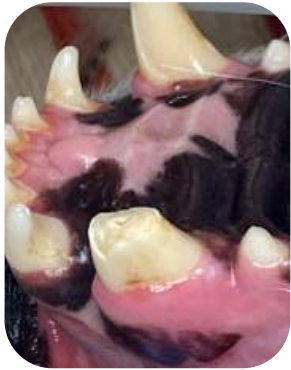- When the tooth has fractured near the gumline, leaving little of the crown to be functional.
- If the fracture extends vertically down the root, significantly below the gum line.
- When the tooth has periodontal (gum) disease as well.
- When the roots of the tooth and/or the bone around the roots have been destroyed due to long-standing infection or inflammation (this is typically not evident until x-rays are obtained).
- In patients with severe medical conditions that would make repeated anesthetic episodes inadvisable.



What is involved in root canal treatment?



1. A small hole is drilled into the tooth over each root – this is called the access.
2. The pulp cavity inside each root is cleaned using special files, and each canal is flushed throughout the filing process to remove all infected and dead tissue.
3. The canal is filled with a sterile, inert material in the space where the pulp used to be.
4. The access is sealed with a tooth-colored composite restorative material.
5. In some cases, a prosthetic metal crown is placed on the tooth after root canal treatment. (the metal crown pictured is on a different dog; the prosthetic crown is not rebuilt to the original tooth height, but rather fit perfectly to the remaining natural crown of the tooth)



These dental radiographs were taken during root canal therapy on two mandibular canine teeth. After measuring how long the root is, we remove the dead pulp, clean the inside of the pulp cavity, then fill it with a sterile material and place composite at the access sites.

Recheck radiographs 6 months after treatment allow us to verify that the filling, bone around the roots, and composite restorations are all intact.

Big cats need dental care too!

- Fractured teeth are common in captive wild animals.
- In order to save fractured teeth that are important for prehension (picking up food), mastication (chewing food), and social status, root canal therapy can be a great option!
- Pictured to the right is a tiger that had fractured her upper right canine tooth before her arrival to her resident zoo.
- Root canal therapy was performed to conserve this tooth while preventing infection and inflammation related to the exposed pulp.
- *Lions and tigers and bears?* Yes! We have helped other animals, too! We have been honored to work on flying foxes, hyenas, cheetahs, snow leopards and a chimpanzee.

